

Open Revision of Failed Arthroscopic Shoulder Reconstructions for Traumatic Instability

Michael J. Pagnani, M.D.
Director, Nashville Knee & Shoulder Center

Despite the increased popularity of arthroscopic techniques for the treatment of anterior shoulder instability, several patient populations appear to remain at high-risk for recurrent instability after arthroscopic stabilization. Contact athletes, patients with bony defects of the humeral head and/or glenoid, those with atraumatic instability or capsular deficiency, and individuals who have sustained humeral avulsion of the glenohumeral ligaments or who have had a concomitant rupture of the subscapularis in association with a dislocation may be at particular risk for failure after arthroscopic repair.

Several possible causes of the relatively high failure rates associated with arthroscopic stabilization have been postulated. Proposed factors associated with failure include capsular laxity and/ or an enlarged rotator interval, lack of placement of an inferior suture anchor (nothing below the 4- or 8 o'clock position on the glenoid), inadequate post-operative immobilization, and the presence of an "engaging" or large Hill-Sachs lesion.

Open methods of anterior stabilization have some inherent advantages over arthroscopic techniques and should be considered as the primary treatment options for patients who have failed an attempt at arthroscopic stabilization.. Open stabilization allows the surgeon to free the glenohumeral capsule from the overlying subscapularis

tendon in order to precisely tension the capsule without undue adherence of the tendon. The rotator interval can be better visualized and tensioned using an open method, and the effects of rotator interval closure on glenohumeral translation and kinematics appear to be different (and more clinically advantageous) with open surgery. Open stabilization provides the ability to double the thickness of the capsular repair, enables the surgeon optimally position the arm during the repair, and allows an assortment of modifications to permit the surgeon to address any bony defects associated with instability.

The surgical outcomes of primary open stabilization, with one exception, have been uniformly excellent with recurrence rates generally in the 3-5% range. (Wirth & Rockwood JBJS, 1996, Gill et al JBJS, 1997) The exception to these high rates of success is the unexplained West Point experience (Uhorchack et al AJSM 2000) with a reported recurrence rate on 22% in a population with a high prevalence of subluxation rather than frank dislocation.

While several concerns have recently been expressed regarding perceived disadvantages of open techniques when compared to arthroscopic methods, a review of the literature is reassuring with regard to the most common purported issues. One such concern is the possibility of subscapularis rupture after open stabilization. Sachs et al reported that 23% of their patients demonstrated an "incompetent subscapularis" after open stabilization. (Sachs et al, AJSM, 2005) This determination was made based on clinical testing alone (a positive "lift-off" test), and only one case was documented by MRI. Shortly thereafter, Schiebel et al expressed similar concerns about subscapularis

function but were unable to document a single case of complete rupture on MRI and found that, while some patients demonstrated a degree of atrophy in the superior portion of the tendon, such atrophy was largely compensated for by hypertrophy of inferior portion. (Scheibel et al, AJSM, 2006) Prior to these reports, rupture of the subscapularis after open stabilization was a reportable case. (Greis et al, JSES, 1996. Rowe et al, JBJS, 1984) In our 25-year experience with the technique, we have not encountered a single case after a procedure performed at our institution. Meticulous attention to closure and preservation of some capsular attachments superiorly and inferiorly while working under the subscapularis may explain the difference between our experience and those of Sachs et al and Schiebel et al.

An associated concern is the possibility of shoulder weakness following open stabilization. However, Hiemstra et al recently demonstrated that there were no side-to-side isokinetic strength differences between groups treated with open versus arthroscopic stabilization at one year after surgery. (Hiemstra et al, AJSM, 2008) Similarly, Rhee et al concluded that muscle strength was equal between open and arthroscopic cohorts at 12 months, although, as one might expect, the open group recovered more slowly than arthroscopic group. (Rhee et al, AJSM, 2007)

In this era of evidence-based medicine, three separate meta-analyses have concluded that the results of open stabilization are superior to those of arthroscopic stabilization. (Freedman, AJSM, 2004, Mohtadi, Arthroscopy, 2005, Lenters et al, JBJS, 2007) In discussion of their paper, Mohtadi et al commented that “open repair has a

more favorable outcome with respect to recurrence and return to activity.” Lenters and Matsen found that arthroscopic stabilization is "not as effective as open in preventing recurrent instability or enabling patients to return to work.” In addition, two non-randomized series have shown significantly lower recurrence rates after open stabilization when compared with arthroscopic techniques despite careful exclusion of patients whose pathologic findings were not felt to be ideal in the arthroscopic group. (Cole et al JBJS, 2000, Hubbell et al AJSM, 2004)

On the other hand, two often-quoted randomized trials comparing open and arthroscopic methods appeared to show similar recurrence rates between the two groups. However, significant confounding issues exist within each of the series. In the Fabbriciani et al study of 60 randomized patients, 44 additional patients were excluded because they were not felt to have arthroscopic findings that were amenable to arthroscopic repair. (Fabbriciani et al Arthroscopy 2004) The West Point series (Bottoni et al, AJSM, 2006) reported a mean operative time of 149 minutes in the open group, suggesting some lack of familiarity with the open technique. (Our mean operative time is around 75 minutes for a similar procedure). The low failure rates in each of these series (no recurrent dislocations in either group in either study) make interpretation difficult and the data somewhat perplexing since the recurrence rates are much lower than those reported results after arthroscopic stabilization in almost all non-randomized series.

Contact athletes have had generally disappointing outcomes after arthroscopic stabilization. Burkhart and deBeer reported a 14% failure in contact athletes despite

relatively short follow-up. (Burkhart & DeBeer, Arthroscopy, 2000) Hubbell et al noted a 60% failure rate in collision athletes who underwent arthroscopic stabilization but had no recurrences in their open group. (Hubbell et al, AJSM, 2004) Similarly, Rhee et al noted that the recurrence doubled (from 12.5% to 25%) when they compared contact athletes who underwent arthroscopic repair to those who had an open stabilization. (Rhee et al, AJSM) Recently, Voos et al (Voss et al AJSM, 2010) found a 26% recurrence in contact athletes with contemporary techniques of arthroscopic stabilization.

Our published experience using a conventional open technique in contact athletes has been favorable. (Pagnani & Dome, JBJS, 2002). In our study of 58 American football players, the recurrence rate was 3% with 2 post-operative subluxations and no dislocations. Fifty-two of the 58 returned to their sport with only one discontinuing due to recurrence. In addition, range-of-motion loss was minimal.

High recurrence rates have also been reported after arthroscopic Bankart repair in patients with bony defects of the humeral head and/or glenoid. (Burkhart & De Beer, Arthroscopy, 2000, Boileau et al JBJS, 2006) A review of the literature on the results of open stabilization in patients with similar defects reveals much more favorable results. Rowe et al reported only a 2% recurrence rate in patients with glenoid rim lesions who underwent open Bankart repair. (Rowe et al JBJS, 1978) They also noted an acceptable 5% recurrence rate in patents with moderate or large Hill-Sachs lesions compared with a 3.5% overall failure rate. Gill et al noted that the presence of a large Hill-Sachs lesion

increased the risk of failure from 3% to a higher but reasonable 6%. (Gill et al JBJS, 1997) Bigliani et al noted a slightly higher recurrence rate of 12% in patients with glenoid rim lesions who were treated with an open capsular shift. (Bigliani et al AJSM, 1998)

In our study of 119 consecutive patients with recurrent anterior instability who were treated with an open technique, the presence of defects of the humeral head and/or glenoid did not significantly increase the risk of post-operative failure. (Pagnani, AJSM, 2008) In the 87 patients in the series with Hill-Sachs lesions, the recurrence rate was equal to the overall population at 2%. In the 28 patients with “engaging” lesions, the rate of failure was 4% and was not statistically higher. In contact athletes, patients with Hill-Sachs lesions had a 3% recurrence and those with engaging lesions had a 5% failure rate. None of the 14 patients with glenoid lesions (including four with defects of greater than 20% of the glenoid surface) suffered a recurrence. The technique also preserved motion: patients with large defect of the humeral lost a mean of only 4 degrees of external rotation while those with large glenoid defect lost an average of 7 degrees.

Our results suggest that bone-block or grafting procedures do not appear to be necessary in the majority of patients with bone loss. Our findings also suggest an inherent difference between open and arthroscopic capsular repair procedures.

Surgical Technique

Initially, the patient is placed supine and is brought as close to the edge of the bed as possible, and an armboard is placed on the operating table on the affected side and aligned with arm. Folded sheets are

then taped to armboard in order to rest the elbow in a position that facilitates shoulder flexion and helps maintain reduction of the joint during the capsular repair. The armboard is placed in an adducted position at the side of the table during the arthroscopic examination.

The head of the bed is then elevated to 60 degrees and the hips and knees are flexed to move the patient into the beach-chair position. The patient is maintained in this position by use of a molded beanbag. Performing an arthroscopic evaluation prior to proceeding with the open repair allows the surgeon to evaluate the patient for concomitant SLAP lesions and posterior pathology that may be difficult to visualize or access through an anterior incision. Rotator cuff injury can also be assessed. Finally, determination of the presence or absence of a Bankart lesion can assist the surgeon in planning for the method of open repair.

When the arthroscopic portion of the procedure has been completed, the bean bag is deflated and the head of the bed is lowered to 15 degrees. The armboard is then pulled out so that the elbow rests on the folded sheets with the arm in approximately 45 degrees of abduction.

Open Bankart Repair

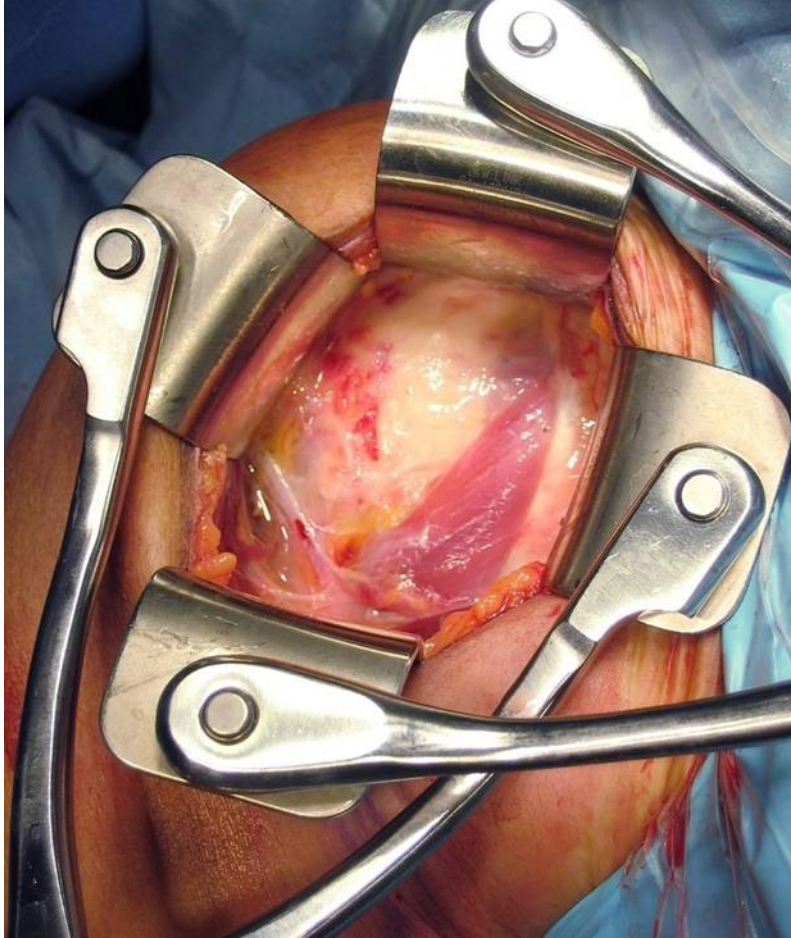
Two assistants are employed throughout the procedure. Initially, the surgeon begins the procedure standing in the axilla with the first assistant lateral to the arm on the other side of the armboard. The second assistant stands on opposite side of table near the contralateral shoulder throughout the case. No armboard should be placed in the contralateral side to reduce the physical demands on the second assistant involved with stretching to reach across the table.

An anterior deltopectoral approach to the shoulder is used. A skin incision measuring 3-6 centimeters (depending on the size and cosmetic desires of the patient) is made along the along anterior axillary crease. (Figure 1)



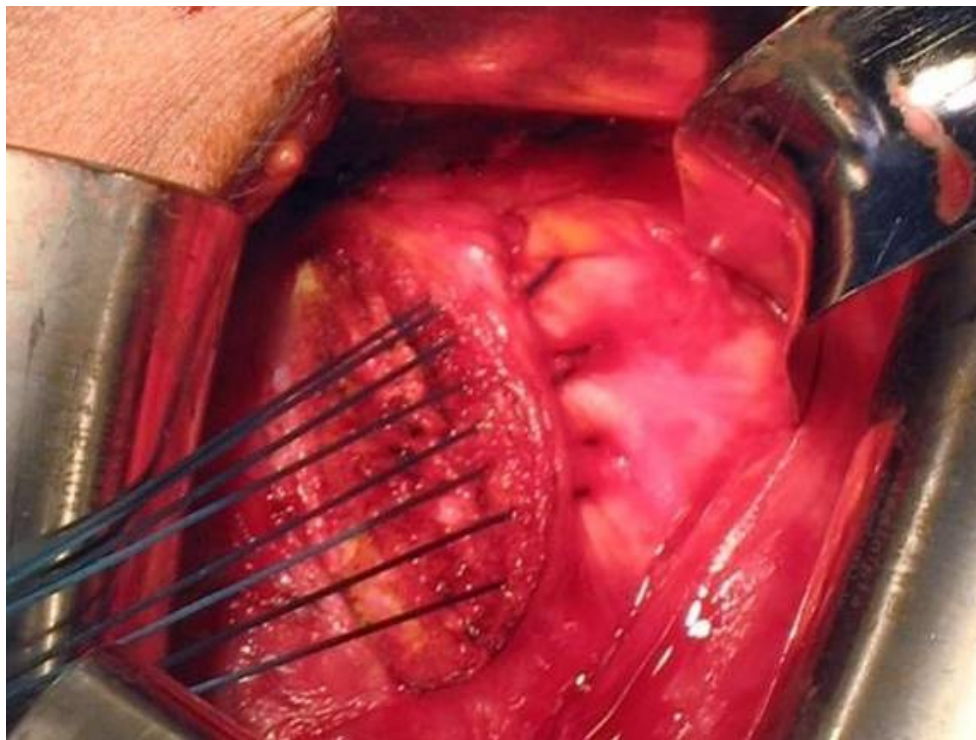
Skin flaps are then developed medially and laterally, and the adipose tissue that overlies the cephalic vein is identified. The vein is then exposed and retracted laterally as the deltopectoral interval is developed. After the temporary placement of hand-held retractors, the clavipectoral fascia is incised just lateral to conjoined tendon., taking care to protect the musculocutaneous nerve.

At this point, self-retaining retractors are used to free hands of the assistants so that optimal arm position and reduction of the glenohumeral joint can be maintained during the capsular repair. We prefer to use two self-retaining retractors: one that spreads the wound from medial-to lateral and a second that spreads the wound from superior-to-inferior. A pair of Kolbel retractors with self-rotating blades have been our preference. (Figure 2)



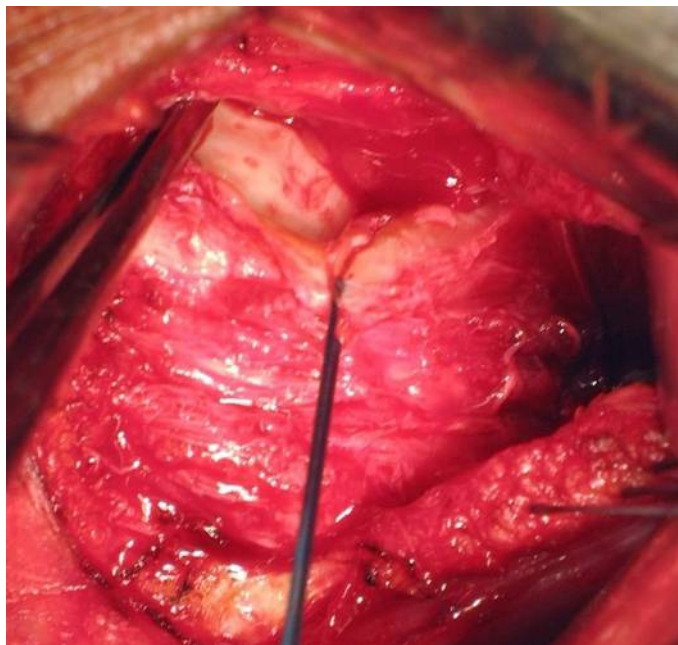
Once the retractors are placed, the hands of the first assistant are free to control arm position and to maintain reduction of the humeral head during capsular repair. At this point, the surgeon moves to the lateral aspect of the arm and the first assistant assumes the position in the axilla.

Except in throwing athletes, the subscapularis is tenotomized rather than split. An electrocautery is used to begin the tenotomy by making a vertical incision in the subscapularis approximately one centimeter medial to the lesser tuberosity. The interval between the subscapularis and the anterior capsule is then developed with a combination of blunt dissection with a small periosteal elevator and sharp dissection with a scalpel. Once the distal aspect has been freed for 4-5 mm, modified Kessler #1 non-absorbable sutures are placed in the distal end of the tendon. (Figure 3)

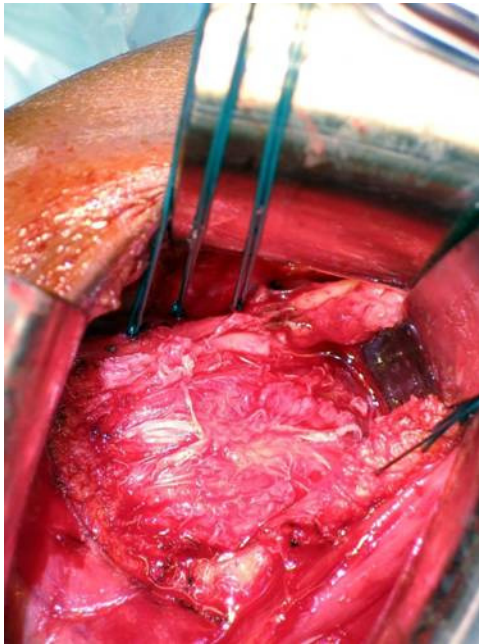


Dissection is then carried medially under the subscapularis down to the glenoid. A larger extracapsular retractor is placed medially on the glenoid.

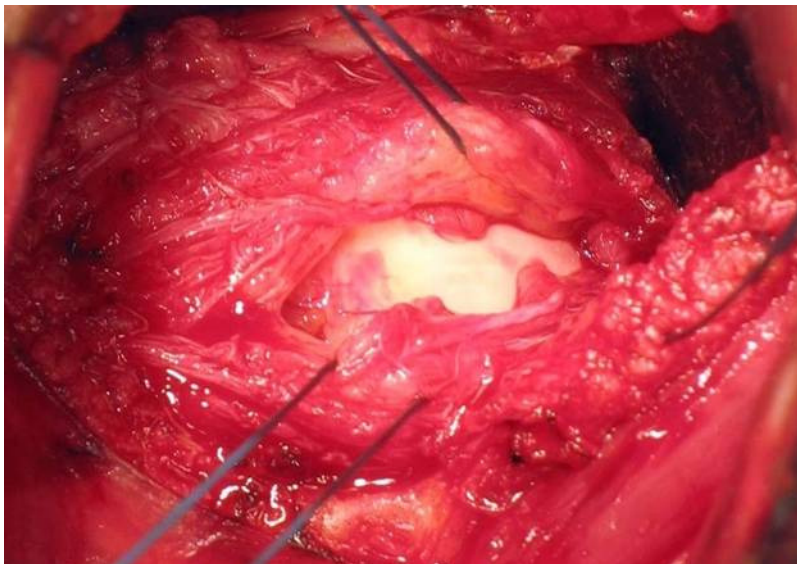
At this point, the rotator interval area between the subscapularis and the supraspinatus is assessed for a defect. (Figure 4)



If a defect is present, it is closed in a horizontal fashion using #1 non-absorbable sutures. (Figure 5)

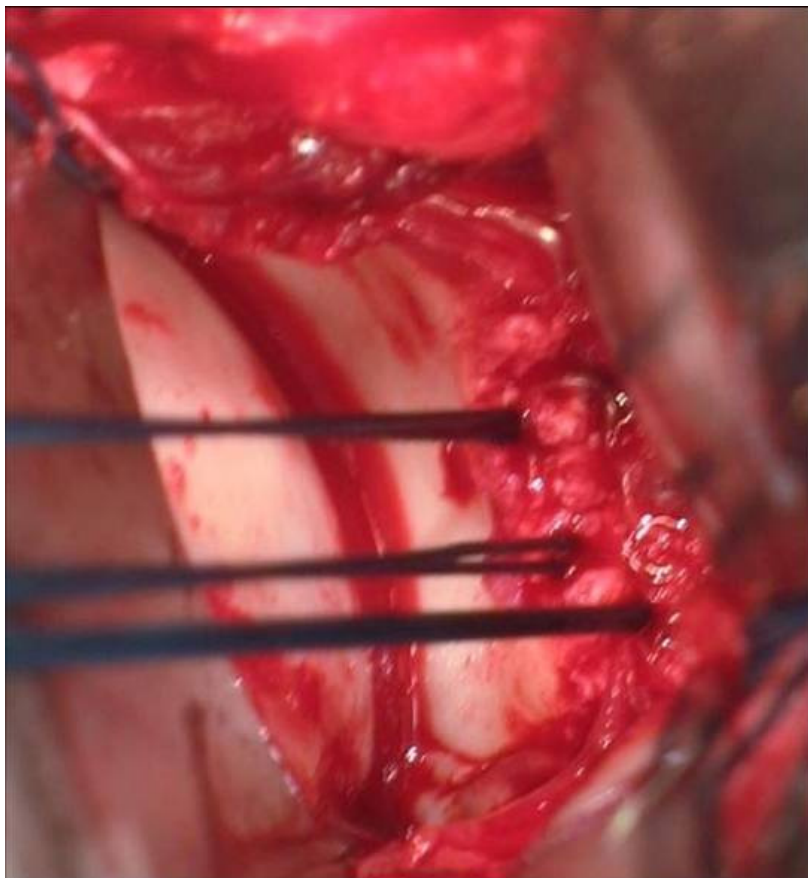


A horizontal capsulotomy is then performed at the junction of the inferior third and the superior two-third of the joint. (Figure 6)

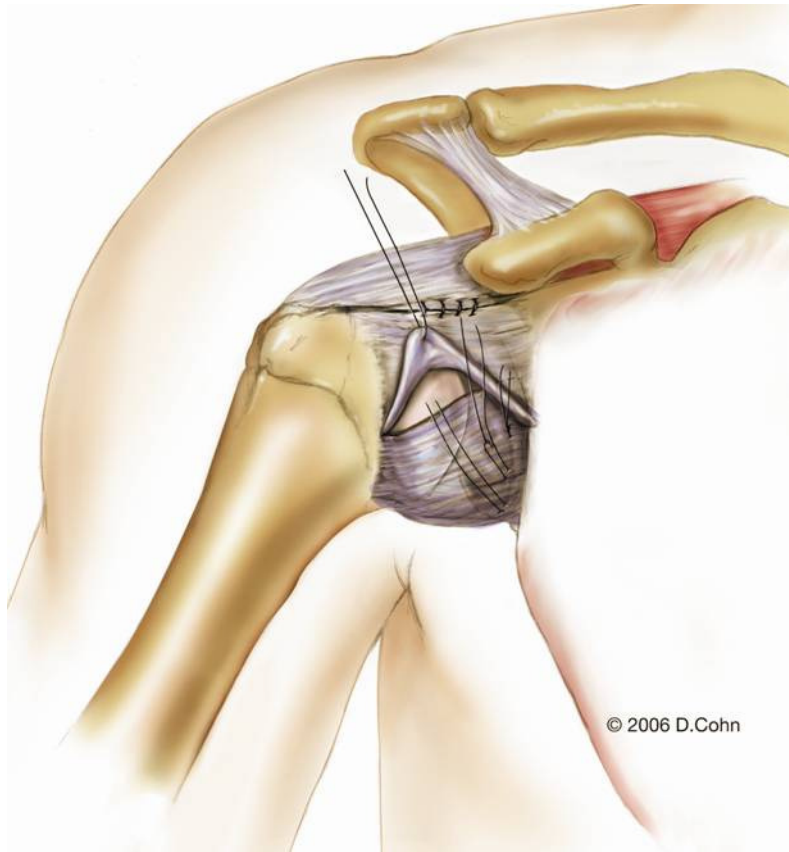


The capsulotomy creates inferior and superior capsular flaps. A humeral head ring retractor is then placed into the joint. A smaller intracapsular retractor is then placed on the glenoid neck and the larger extracapsular retractor is removed. The presence or absence of a Bankart lesion is confirmed.

If a Bankart lesion is present, the glenoid neck is debrided to bleeding bone using a motorized burr. Two-to-three suture anchors are then generally placed on the glenoid neck near the articular margin but not within the joint cavity. (Figure 7)

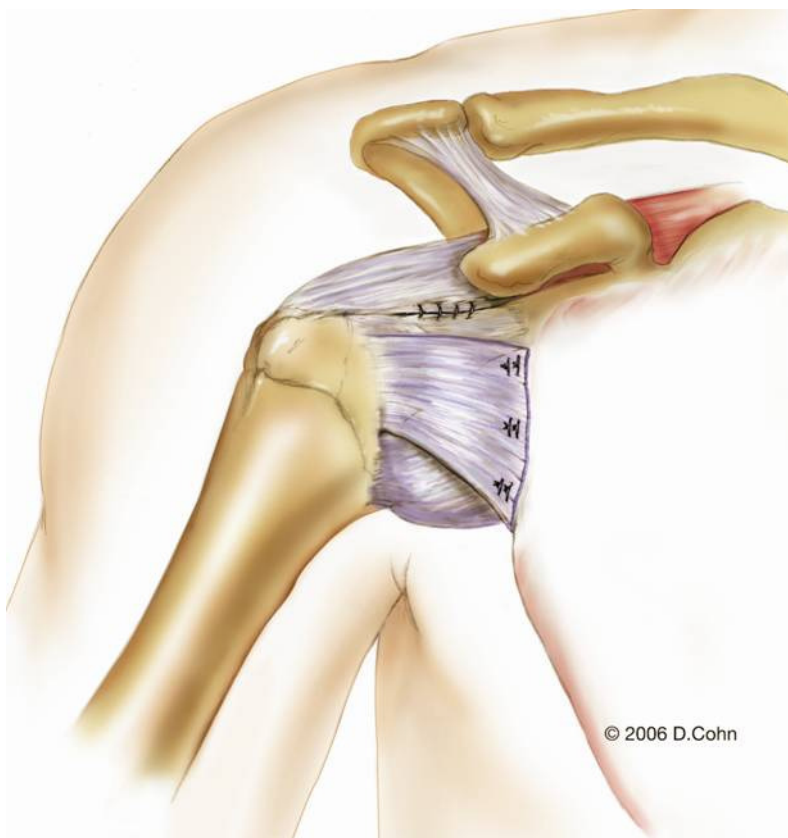


The inferior capsular flap is used to repair the Bankart lesion. With the arm held in 45 degrees of abduction and 45 degrees of external rotation and reduction of the humeral head maintained by the first assistant, the sutures from the most inferior anchor are passed first as the inferior flap is mobilized superomedially. Additional sutures are then passed as the flap is repaired to the more superior anchors. The sutures are then tied with the arm maintained in the 45/45 position and the shoulder reduced. (Figure 8)

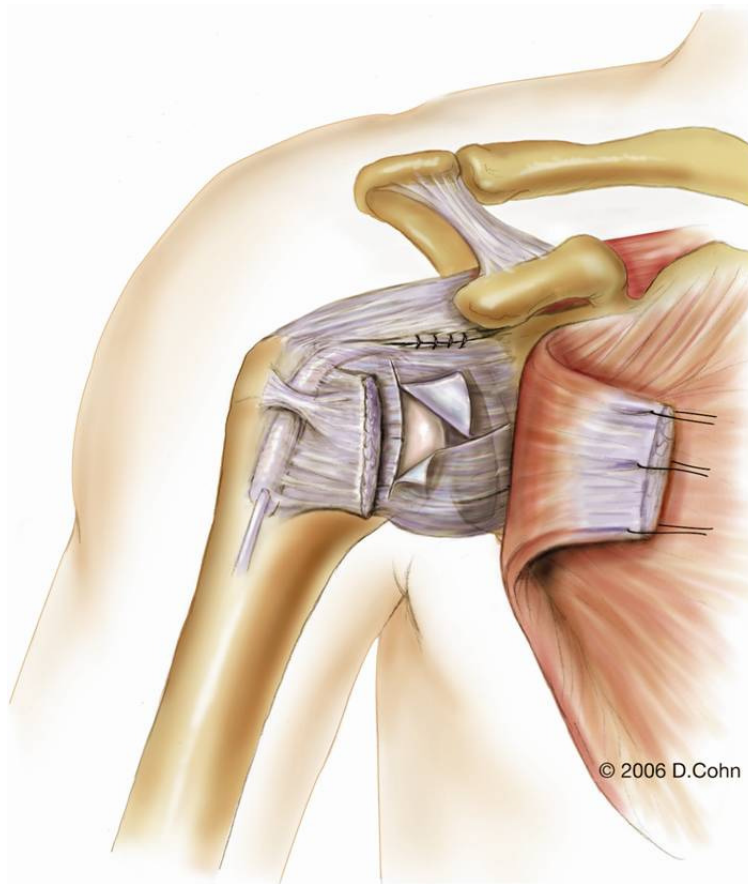


The same sutures are then passed through the superior flap, starting with the most superior anchor first. The superior flap is mobilized inferomedially to eliminate any residual capsular laxity and to double the capsular thickness. After passing the sutures associated with the more inferior anchors, the sutures are

tied with the arm remaining in the 45/45 position. (Figure 9)

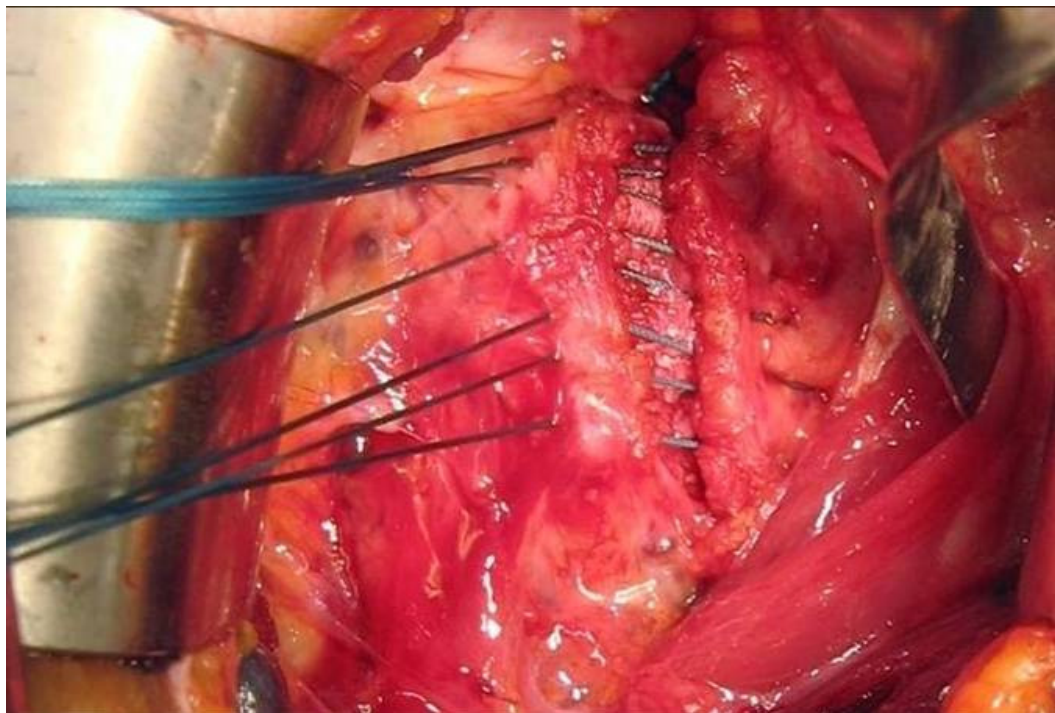


After repair of the Bankart lesion (or in the absence of a Bankart lesion), an anterior capsulorrhaphy is performed to eliminate excess capsular laxity. If the remaining capsular flaps can be overlapped, the capsule is shifted to eliminate excess capsular volume. If there are 5 millimeters (or less) of overlap at any point along the horizontal capsular incision, the capsule is imbricated by shifting the superior flap over the inferior flap and passing the sutures a second time through the superior flap. With greater than 5 millimeters of capsular overlap, the capsulotomy is extended in a vertical direction near its lateral insertion on the humeral neck to approximately the “six o’clock” position on the neck, and a T-plasty capsular shift is performed (Figure 10).



The inferior capsular flap is shifted superolaterally and the superior flap was moved over the inferior flap in an inferolateral direction. The transverse portion of the capsulotomy is then closed.

The tagging sutures in the subscapularis are then used to reattached the tendon to the remaining stump medial to the lesser tuberosity. (Figure 11)



The repaired tendon is reinforced with #0 absorbable suture to create a smooth tendon surface.

Special Situations:

Glenoid Bony Defect

We do not usually modify our technique in the presence of a glenoid rim defect. We will consider bone graft or bone block to the glenoid only if more than 1/3 of glenoid is deficient and usually in the revision patient. In these cases with larger defects, the Latarjet procedure appears to be superior to the Bristow procedure in that it provides a larger portion of coracoid to compensate for the large degree of glenoid loss.

Hill-Sachs Defects:

We do not modify our technique in the presence of most Hill-Sachs lesions. We have (again in the revision patient) performed osteochondral allograft reconstruction in selected patients with large Hill-Sachs defects that involve more than 25% of the humeral head and that are more than one centimeter deep. Such grafting can be performed through a second, lateral deltoid-splitting incision.

Capsular Deficiency

In the difficult revision patient who has failed multiple previous procedures or who has suffered capsular necrosis after arthroscopic thermal capsulorraphy, the capsule may be insufficient to allow the methods of repair described above. In these cases, we have preferred to use hamstring grafts (autograft or allograft) that are fixed to the humeral neck and glenoid with suture anchors or drill holes and then brought back and forth from lateral-to-medial to try to recreate the capsular ligaments. (Alcid et al, J Shoulder Elbow Surg, 2007) The arm is usually maintained in 0-30 degrees of external rotation for these difficult cases as motion is sacrificed to attain some semblance of stability.

Results of Open Revision of Failed Arthroscopic Stabilizations

The results of open revision of failed arthroscopic stabilizations (Sisto AJSM 2007, Cho et al AJSM 2009) appear to be superior to those reported for open revision of failed open stabilization. (Rowe et al JBJS 1984, Levine et al AJSM 2000, Zabinski et al JSES, 1999) Sisto (Sisto AJSM 2007) reported that 87% of patients had good or

excellent results with no cases of recurrent instability in a group of 30 patients who underwent open revision of arthroscopic failures. Similarly, Cho et al (Cho et al, AJSM, 2009) found that 88% of their open revisions of arthroscopic failures had good or excellent results although they did note an 11% recurrence rate.

Even patients who have failed arthroscopic thermal capsulorrhaphy also have fared reasonably well after open revision. Massoud et al reported success in 9 of 10 patients revised with an open capsular shift (Massoud et al JSES, 2002) and Park et al (Park et al AJSM, 2005) had an 86% success rate in their series of 14 patients.

In contrast, Levine et al (Levine et al, AJSM, 2000) reported a 22% recurrence rate after open revision for open failure and Zabinski et al (Zabinski et al, JSES, 1999) had a 26% failure rate in a similar series.

REFERENCES:

Alcid JG, Powell SE, Tibone JE: Revision anterior capsular shoulder stabilization using hamstring tendon autograft and tibialis tendon allograft reinforcement: minimum two-year follow-up. *J Shoulder Elbow Surg.*16:268-72, 2007

Bigliani LU, Newton PM, Steinmann SP, Connor PM, McIlveen SJ: Glenoid Rim Lesions Associated with Recurrent Anterior Dislocation of the Shoulder. *Am J Sports Med* 26:41-45, 1998.

Boileau P, Villalba M, Hery J-Y, Balg F, Ahrens P, Neyton L: Risk Factors for Recurrence of Anterior Instability After Arthroscopic Bankart Repair. *J Bone Joint Surg* 88-A: 1755-1763, 2006

Bottoni CR, Smith EL, Berkowitz MJ, Towle RB and Moore JH. Arthroscopic Versus Open Shoulder Stabilization for Recurrent Anterior Instability: A Prospective Randomized Clinical Trial. *Am. J. Sports Med.* 2006; 34; 1730

Burkhart SS, De Beer JF: Traumatic glenohumeral bone defects and their relationship to failure of arthroscopic Bankart repairs: significance of the inverted-pear glenoid and the humeral engaging Hill-Sachs lesion. *Arthroscopy* 16: 677-694, 2000.

Cho NS, Yi JW, Lee BG, Rhee YG: .Revision open Bankart surgery after arthroscopic repair for traumatic anterior shoulder instability. *Am J Sports Med.* 37(11):2158-64, 2009

Cole BJ, L'Insalata J, Irrgang J, Warner JJP. Comparison of arthroscopic and open anterior shoulder stabilization: A two to six-year follow-up study. *J Bone Joint Surg* 82-A: 1108-1114, 2000.

Fabbriciani C, Milano G, Demontis A, Fadda S, Ziranu F, and Mulas PD, M.D Arthroscopic Versus Open Treatment of Bankart Lesion of the Shoulder: A Prospective Randomized Study *Arthroscopy: The Journal of Arthroscopic and Related Surgery*, Vol 20, No 5 (May-June), 2004: pp 456-462.

Freedman KB, Smith AP, Romeo AA, Cole BJ, Bach BR Jr Open Bankart Repair Versus Arthroscopic Repair With Transglenoid Sutures or Bioabsorbable Tacks for Recurrent Anterior Instability of the Shoulder: A Meta-analysis. *Am. J Sports Med* 32: 1520–1527, 2004.

Gill TJ, Micheli LJ, Gebhard F, Binder C. Bankart repair for anterior instability of the shoulder. Long-term outcome. *J Bone Joint Surg* 79-A: 85-857, 1997.

Greis PE, Dean M, Hawkins RJ. Subscapularis tendon disruption after Bankart reconstruction for anterior instability. *J Shoulder Elbow Surg* 1996;5:219-22

Hiemstra LA, Sasyniuk TM, Mohtadi NGH, and Fick GH: Shoulder Strength After Open Versus Arthroscopic Stabilization. *Am J Sports Med* May 2008 36:861-867.

Hubbell JD, Ahmad S, Bezenoff LS, Fond J, and Pettrone FA. Comparison of Shoulder Stabilization Using Arthroscopic Transglenoid Sutures Versus Open Capsulolabral Repairs: A 5-Year Minimum Follow-up. *Am J Sports Med* 32: 650–654, 2004.

Lenters TR, Franta AK, Wolf FM, Leopold SS, Matsen FA 3rd. Arthroscopic compared with open repairs for recurrent anterior shoulder instability. A systematic review and meta-analysis of the literature. *J Bone Joint Surg Am.* 2007 Feb;89(2):244-54

Levine WN, Arroyo JS, Pollock RG, Flatow EL, Bigliani LU. Open revision stabilization surgery for recurrent anterior glenohumeral instability. *Am J Sports Med* 28:156-160, 2000

Massoud SN, Levy O, Copeland SA. Inferior capsular shift for multidirectional instability following failed laser-assisted capsular shrinkage. *J Shoulder Elbow Surg.* 2002;11(4):305–308,

Mohtadi NG, Bitar IJ, Sasyniuk TM, Hollinshead RM, Harper WP. Arthroscopic versus open repair for traumatic anterior shoulder instability: a meta-analysis. *Arthroscopy.* 2005 Jun;21(6):652-8.

Pagnani MJ: Open Capsular Repair Without Bone Block of Anterior Instability in Patients with and Without Bony Defects of the Glenoid and/or Humeral Head. *Am J Sports Med* 36: 1805-1812, 2008

Pagnani MJ, Dome DC: Surgical treatment of traumatic anterior shoulder instability in American football players: two-to-six year follow-up in fifty-eight athletes. *J Bone Joint Surg* 84-A: 711-715, 2002.

Park HB, Yokota A, Gill HS, El Rassi G, McFarland ES: Revision Surgery for Failed Thermal Capsulorrhaphy *Am J Sports Med* 33: 1321-1326, 2005.

Rhee YG, Ha IH, and Cho NS: Anterior Shoulder Stabilization in Collision Athletes. *Am J Sports Med.* June 2006 34:979-985.

Rhee YG, Lim CT, and Cho NS: Muscle Strength After Anterior Shoulder Stabilization. *Am J Sports Med.* November 2007 35:1859-1864.

Rowe C, Patel D, Southmayd W. The Bankart procedure: a long-term end-result study. *J Bone Joint Surg* 60-A: 1-16, 1978.

Rowe CR, Zarins B, Ciullo JV. Recurrent anterior dislocation of the shoulder after surgical repair: apparent causes of failure and treatment. *J Bone Joint Surg Am.* 1984;66:159-168.

Sachs RA, Williams B, Stone ML, Paxton L, and Kuney M: Open Bankart Repair. *Am J Sports Med.* October 2005 33:1458-1462.

Scheibel M, Tsynman A, Magosch P, Schroeder RJ, and Habermeyer P: Postoperative Subscapularis Muscle Insufficiency After Primary and Revision Open Shoulder Stabilization. *Am J Sports Med* October 2006 vol. 34 no. 10 1586-1593

Sisto DJ: Revision of Failed Arthroscopic Bankart Repairs. *Am J Sports Med* 35:537-541, 2007.

Uhorchak JM, Arciero RA, Huggard D, Taylor DC. Recurrent Shoulder Instability After Open Reconstruction in Athletes Involved in Collision and Contact Sports. *Am J Sports Med* 28: 794-799, 2000.

Voos JE, Livermore RW, Feeley BT, Altchek DW, Williams RJ, Warren RF, Cordasco FA, and Allen AA: Prospective Evaluation of Arthroscopic Bankart Repairs for Anterior Instability, *Am J Sports Med* 38. 302-307, 2010.

Wirth MA, Blatter G, Rockwood CA Jr. The Capsular Imbrication Procedure for Recurrent Anterior Instability of the Shoulder. *J Bone Joint Surg* 78-A: 246-260, 1996..

Zabinski SJ, Callaway GH, Cohen S, Warren RF: Revision shoulder stabilization: 2- to 10-year results. *J Shoulder Elbow Surg* 8:58-65, 1999